

## Surgical Anatomy of the Anterior Cervical Spine: The Disc Space, Vertebral Artery, and Associated Bony Structures

T. Glenn Pait, M.D., James A. Killefer, M.D.,  
Kenan I. Arnautovic, M.D.

Department of Neurosurgery, University of Arkansas for Medical Sciences, Little Rock, Arkansas (TGP, KIA), and Department of Neurosurgery (AKI), West Virginia University, Morgantown, West Virginia

**OBJECTIVE:** To elucidate the relationships between the neurovascular structures and surrounding bone, which are hidden from the surgeon by soft tissue, and to aid in avoiding nerve root and vertebral artery injury in anterior cervical spine surgery.

**METHODS:** Using six cadaveric spines, we measured important landmarks on the anterior surface of the spine, the bony housing protecting the neurovascular structures in the lateral disc space, and the changes that occur during the discectomy with interbody distraction of the vertebral bodies. The measurements included the distance between the medial borders of the longus colli muscle at the level of each interspace; the width and height of each disc space at the midline; the width and height of the costal process; the distances between the cranial tip of the uncinate process (UP) and the vertebral body (VB) above and from the tip of the UP to the vertebral artery; the anteroposterior diameter or the extent of the disc spaces in the midline; the height at the midpoint of the distracted disc space; the UP-VB distance in distraction; and the width of the visible nerve root.

**RESULTS:** The distance between the medial borders of the longus colli muscles increased in a rostral to caudal direction. The height of the UP was shortest at C4–C5 and greatest at C5–C6; the width was narrowest at C4–C5 and widest at C6–C7. The width of the costal process measured from the VB to the anterior tubercle was narrowest at C2–C3 and widest at C6–C7. The midpoint height of the costal process was smallest at C6–C7 and tallest at C4–C5 and C5–C6. The nondistracted UP-vertebral artery distance was the shortest at C2–C3 and longest at C4–C5. The nondistracted UP-VB distance averaged 1 mm at C2–C3 and C6–C7 and 1.5 mm at C4–C5. The height of the distracted disc space was shortest at C2–C3 and C6–C7. The UP-VB distance after distraction was greatest at C4–C5. Only at the C2–C3 interspace was the nerve always above the process. The vertebral artery entered the foramen transversarium of C6 in all the specimens.

**CONCLUSION:** Although avoiding unfortunate injury is not always possible, understanding the locations and relations among the anatomic features is the only safeguard against unwarranted damage. (*Neurosurgery* 39:769–776, 1996)

*Key words:* Costal process, Longus colli muscles, Uncinate process, Vertebral artery

The anterior surgical approach to the cervical spine, now a commonly used procedure, was advocated as early as the 19th century. Advances in anesthesia and chemotherapy and the recognition of architectural principles in arthrodesis paved the way for developments of surgical approaches to the spine.

Henderson, in 1917 (23), argued that posterior fusion, which had no effect on the diseased anatomy, was an ineffective procedure for tuberculosis of the spine. The need for a more effective, radical therapy for Pott's disease prompted the development of different approaches to the anterior spine (25,

27, 32, 49, 50). Bailey and Badgely (2) note that in 1952, L.C. Abbott first suggested the use of an anterior fusion for a case of a lytic lesion of C4 and C5. Because of the ease of the approach, the technique became popular for treating other cervical spine lesions, including fractures, neoplasms, and infections. The treatment of degenerative disease of the disc was advanced by Robinson and Smith (38) and Cloward (10), who used the technique of interbody fusion. By 1956, Hodgson and Stoes concluded (23): "The anterior approach to the spinal column is a practicable proposition at all levels and is the only approach which allows accurate visual assessment of

the extent of the disease.<sup>7</sup> The anterior spine was no longer an unapproachable island.

Anterior metal plate-and screw fixation with bone fusions was developed in the mid-1970s, and many refinements of this technique followed (3-7, 33, 47). With the improvements in instrumentation and internal fixation devices, the anterior approach has become a commonly used procedure to treat degenerative disc disease, spondylosis, fractures, and benign and malignant bone tumors (28, 31).

Intraoperative complications of anterior cervical spine surgery after the anterior soft tissue has been dissected include injury to the nerve root, the vertebral artery (VA), and the spinal cord. Data collected by Graham (19) suggest that nerve root injuries are more common than spinal cord injuries. Injuries to the VA during anterior cervical spine surgery are infrequent, but they can be catastrophic (26, 43, 44), often resulting in significant ischemic neurological injuries (27, 26, 39, 40, 41). Smith et al. (44) reviewed 10 cases of such injuries and found the most common cause to be lateral bone resection. Flynn (14), in a survey of 82,114 anterior cervical discectomy and fusion procedures, reported a 0.19% incidence of postoperative radiculopathy.

Avoidance of nerve root and VA injuries in anterior cervical spine surgery requires that the surgeon have an understanding of the relationships between the neurovascular structures and their bony surroundings. However, two major obstacles hinder obtaining this knowledge. First, the anatomy lateral to the disc space is hidden from the surgeon by soft tissue and surrounding bone; second, the relationships between bony and neurovascular structures change after discectomy and vertebral body (VB) distraction. To elucidate the anatomy of the nerve root and VA in the anterior approach, we studied this anatomy in cadaveric spines, aged 61 to 85 years. We measured important landmarks on the anterior surface of the spine, the bony housing protecting the neurovascular structures in the lateral disc space, and the changes that occur during the discectomy with interbody distraction of the VBs.

## MATERIALS AND METHODS

Six formalin-fixed cervical spines were removed from adult cadavers, aged 61 to 85 years. All measurements were made using 1) a protractor to define the distance between points and 2) a steel millimeter ruler to measure the distances. All measurements were made at the C2-C3, C3-C4, C4-C5, C5-C6, and C6-C7 levels. Soft tissue superficial to the longus colli muscles was removed, and the distances between the medial borders of the longus colli muscles were measured at the level of each interspace (Fig. 1). The longus colli muscles were then resected. The width space and height of each disc space at the midline were measured. The anteroposterior (AP) diameter (depth) of the disc spaces was also measured.

The uncinate processes (UPs) ("uncus," Latin for "hooked" or "curved") are bony excrescences located laterally and posterolaterally at C3-C7 (3, 35). A line extending laterally from the rostral edge of each VB was marked (a). The bony prominence extending above this line was defined as the UP. A perpendicular line (b) drawn from line (a) to the cranial tip of



**FIGURE 1.** All soft tissue, superficial to the longus colli muscle, removed. Distance between the medial borders of the longus colli muscle was measured at each interspace.

the UP was measured as the height. The width (a) was measured from the medial to the lateral surfaces of the UP at its midportion site (Fig. 2).

The costal process (CP) is the anterior bony segment of the foramina transversarium located laterally from the VB to the anterior tubercle (Figs. 2 and 3) (45). The width (a) was measured from the midpoint on the lateral margin of the VB to the anterior tubercle (Fig. 2). The height (b) of the CP was measured from the cranial to the caudal borders (Fig. 2). The distances between the cranial tip of the CP and the VB above and from the tip of the CP to the VA were measured (Fig. 4).

The intervertebral disc was then removed from each interspace. VB distraction screws were placed into the VBs (Ruggles, Atlanta, GA). The interspace was distracted using the technique for VB distraction described by Caspar et al. (7). The AP diameter or the extent of the disc space was measured in the midline. The posterior longitudinal ligament was excised (Fig. 5). The height at the midpoint of the distracted disc space, the UP-VB distance in distraction, and the width of the visible nerve root were measured (Figs. 3 and 6).

## RESULTS

The distance between the medial borders of the longus colli muscles increased in a rostral to caudal direction. The average distances at the interspaces were: C2-C3, 4.5 mm; C3-C4, 6.7 mm; C4-C5, 11.3 mm; C5-C6, 23.7 mm; and C6-C7, 23.5 mm. The width of the disc spaces was found to vary from 23 mm (at C2-C3) to 28.7 mm (at C6-C7). The height of the disc space

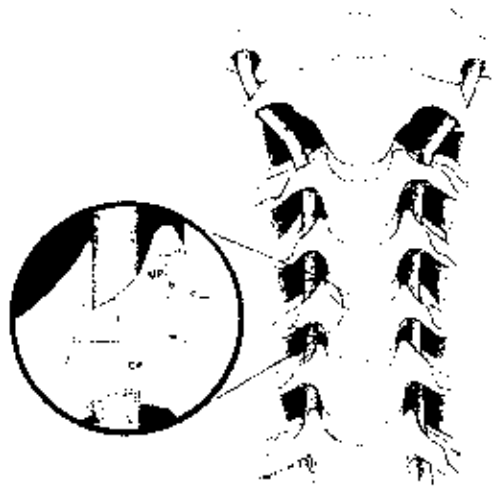


FIGURE 2. UP, the bony prominence above a line ( $c$ ) extending laterally from the rostral edge of each VB, and the CP, the anterior bony segment of the foramina transversarium. The width ( $a$ ,  $w$ , respectively) and height ( $b$ ,  $h$ , respectively) of each were measured.

was found to be lowest at C4-C5 (average, 3.3 mm) and highest at C5-C6 (average, 4.3 mm). The AP diameter (depth) of the disc spaces had an average of 17.9 mm at C2-C3 to 20.8 mm (at C6-C7) (Table 1).

The height of the UP was shortest at C1-C5 (average, 5.8 mm) and greatest at C5-C6 (average, 8.1 mm). The width of the UP was narrowest at C4-C5 (5.3 mm) and widest at C6-C7 (6.7 mm) (Table 2).

The width of the CP measured from the VB to the anterior tubercle was narrowest at C2-C3 (11.3 mm) and widest at C6-C7 (24.8 mm). The midpoint height of this process was shortest at C6-C7 (7.3 mm) and tallest at C4-C5 and C5-C6 (10.8 mm) (Table 1).

The nondistracted distance from the tip of the UP to the nearby VA (UP-VA distance) was the shortest at C2-C3 (0.8 mm) and the longest at C4-C5 (1.6 mm). The nondistracted distance from the tip of the UP to the VB above (LP-VB distance) averaged 1 mm at C2-C3 and C6-C7 and 1.5 mm at C4-C5 (Table 2).

The height of the distracted disc space was shortest at C2-C3 and C6-C7 (average, 8.5 mm) (Table 3). The distance from the tip of the LP to the VB above (UP-VB) after distraction was greatest at C4-C5 (4.5 mm) (Table 3). After distraction, the nerve root was located either above or below the UP. Only at the C2-C3 interspace was the nerve always above the



FIGURE 3. Costal process of the foramina transversarium is identified, as well as the vertebral artery.

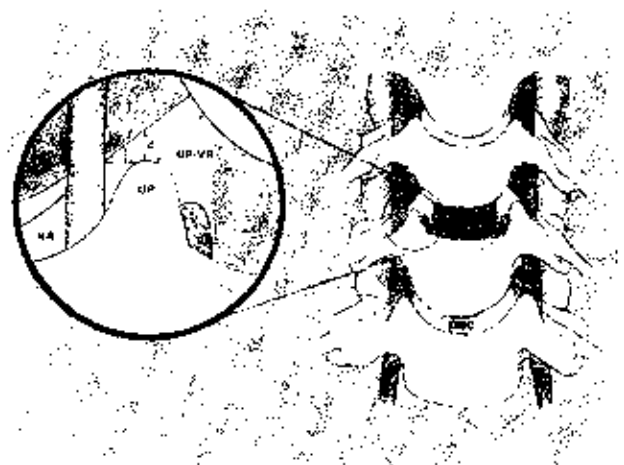


FIGURE 4. Distances ( $d$ ) between the cranial tip of the UP and the VB (UP-VB) and the tip of the UP to the VA (UP-VA) and the distance ( $d$ ) from the tip of the UP up to the nerve root (NR) were measured.

process (average, 1.7 mm) (Table 3). In this study, the VA entered the foramen transversarium of C6 in all the specimens.

## DISCUSSION

Injury to the VA and nerve root are uncommon but serious complications of anterior cervical spine surgery. The true incidence of VA injury during anterior cervical spine surgery



FIGURE 5. The posterior longitudinal ligament was excised after the dissection of the VBs.

is unknown because of underreporting of such occurrences (17). The increased uses of anterior instrumentation and more aggressive anterior cervical procedures portend more frequent mishaps. The best means of preventing complications is possessing knowledge of the surrounding anatomy that is not in direct view, but is in harm's way. To gain this understanding, we used cervical spines from six adult cadavers to measure the landmarks encountered in this approach, placing an emphasis on the bony surroundings of the neurovascular elements in the lateral disc space. By opening the disc space using a VB screw distractor (Ruggles), we also determined the extent to which the nerve root and VA are exposed to injury.

The longus colli muscles extend longitudinally along the ventral surface of the VBs (Fig. 1). The paired muscles are present from C1 to the upper thoracic spine (13) and are attached laterally to the anterior tubercles at the lateral aspect of the CP. The medial borders of these muscles have been suggested as landmarks for determining safe lateral margins for a cervical corpectomy (14). Our data demonstrate that the distance between these muscles increases in a caudal direction. However, considerable variability occurred at each level; therefore, using the medial border of the longus colli as a landmark should be done with caution because doing so may leave behind bone that should be removed. The preferred procedure is to dissect the longus colli muscles to their lateral margins to determine the true bony surfaces of the VBs to be removed. Subperiosteal dissection of the muscles to the beginning of the CP provides sufficient exposure in most cases. If more direct visualization of the lateral boundary of the VB

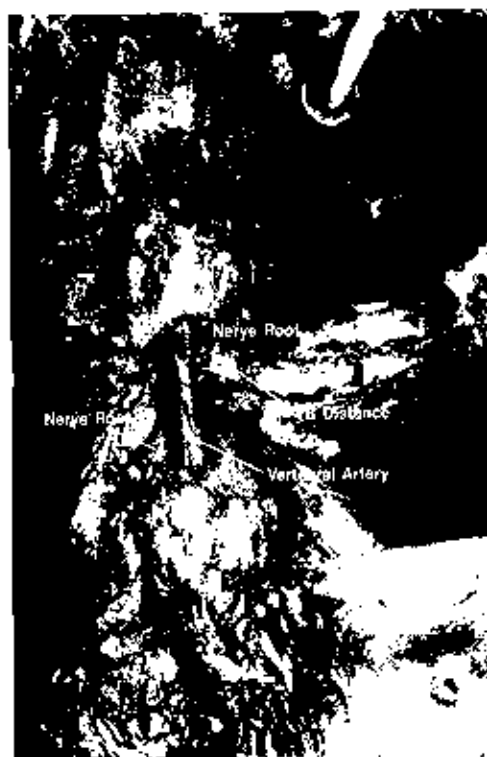

FIGURE 6. Demonstration of the Caspar technique for VB distraction. The distraction screws are seated, UP-VB distance is demonstrated. The nerve root after distraction is well defined.

is needed, as may be the case in tumor resection, the longus colli muscles can be taken off the CPs (Fig. 7). However, caution must be used for this exposure.

The CP in the cervical spine arises from the most ventral extension of the sclerotomic mesenchyme (1, 9). It extends laterally from the VB to the anterior tubercle and is the anterior boundary of the foramen transversarium, lying ventral to the VA (Figs. 3 and 7). Between the adjacent CPs, the VA is protected anteriorly by only small intertransversarii muscles (Figs. 3 and 7) (15). The CP can be exposed surgically by subperiosteal elevation of the longus colli muscle laterally from its medial border.

The CP was narrowest at C2-C3 (11.3 mm) and greatest at C6-C7 (24.8 mm). Therefore, as muscle is dissected from the CP, there is less bony protection of the underlying VA in the upper cervical spine. For far lateral exposure of bony and vascular structures, first exploring the CP is helpful because it allows for easy localization of the underlying VA (Fig. 7). After the CP has been exposed, the dissection can safely proceed along the intertransversarii muscles. If the artery must be exposed, the CP is easily removed by freeing the underlying soft tissue and vascular structures with blunt dissection and then carefully removing the CP with a small rongeur or dissecting drill. The CP is an important door that may be opened to expose the VA.

The UP is located in the superior surface of the cervical VBs, except the first and second, and also on the first thoracic

**TABLE 1. Average and Range of Measurements at Disc Interspaces (mm)**

	C2-C3	C3-C4	C4-C5	C5-C6	C6-C7
Distance between medial borders of longus colli muscles	4.5 (0-8)	6.7 (5-10)	11.3 (7-16)	13.7 (11-20)	23.5 (9-21)
Width of disc space	23 (19-28)	22 (20-25)	24.2 (23-27)	25.4 (21-30)	28.7 (28-35)
Height of disc space	4 (2-6)	4.2 (3-6)	5.3 (1-6)	4.5 (2-7)	4.3 (3-6)
Anteroposterior diameter (depth) of disc space	17.9 (13-19)	19.8 (17-24)	18.8 (16-23)	20.7 (19-24)	20.8 (20-23)
Width of costal process	11.3 (9-13)	11.9 (10-15)	12.8 (11-16)	12.9 (11-19)	24.8 (18-32)
Height of costal process	8.2 (6-12)	8.3 (7-12)	10.8 (7-11)	10.8 (7-11)	7.3 (4-9)

**TABLE 2. Average and Range of Measurements Relative to the Uncinate Processes (mm)**

	C2-C3	C3-C4	C4-C5	C5-C6	C6-C7
Width of uncinate process	6 (5-10)	6.1 (4-10)	5.3 (4-7)	5.8 (4-8)	6.7 (4-8)
Height of uncinate process	6 (4-10)	7.5 (5-10)	5.8 (4-9)	8.1 (7-9)	6.4 (4-10)
Distance from tip of uncinate process to vertebral artery	0.8 (0-3)	1.3 (0-2)	1.6 (0-3)	1.4 (0-3)	1 (0-6)
Distance from tip of uncinate process to vertebral body above	1 (0-3)	1.3 (0-3)	1.5 (0-3)	1.4 (0-3)	1 (0-3)

**TABLE 3. Average and Range of Measurements after Distraction (mm)**

	C2-C3	C3-C4	C4-C5	C5-C6	C6-C7
Height of distracted disc space	8.5 (6-9)	8.8 (6-10)	8.8 (8-11)	9 (6-13)	8.5 (6-11)
Distance from tip of uncinate process to vertebral body above	4.3 (3-6)	4.5 (4-6)	3.7 (3-5)	3.4 (2-5)	3.3 (2-5)
Nerve root visible above uncinate process	1.7 (1-4)	0 (2-1)	1.6 (1-3)	0.8 (1-3)	0.8 (1-4)

vertebra (35). Luschka (30, 35), in 1858, referred to this lip of bone as the "eminentia costaria" because it resembled the head of a rudimentary rib. In 1893, Troard (33, 48) introduced the term "processus uncinatus." Payne and Spillane (35) in their anatomicopathological study of the cervical spine stated that the UP, to some extent, was protective in restricting lateral flexion. With aging, the UP may lose its sharp, tapered configuration and become flattened (3).

Luschka (13, 30) found a narrow cavity between the UP and the inferior "facet" of the superior adjacent vertebra. He considered that they were true lateral intervertebral joints, which contained synovial fluid and were lined by membrane with papillary processes (30, 35); they became known as "Luschka joints." A great debate arose concerning the true anatomic nature of these joints, namely whether they are true or pseudo joints. Many investigators argued that the Luschka joints are simple fissures in fibrocartilage (20, 35, 37), whereas others considered the uncovertebral fissures a type of articulation because of the two fiber layers in the lateral annulus and the nature of the outer "capsule-membrane" (29). Haggund (21), in 1942, concluded after studying 40 cadaver cervical spines that the uncovertebral fissure was an early sign of disc degeneration. Further detailed study indicated that the Luschka articulations are constant, normal, and necessary features of the cervical spine (8). Payne and Spillane (35) found that uncovertebral fissures were present in their specimens; however, a

synovial membrane was never detected by histological examinations. Although they did not believe the fissures were post-mortem artifacts, they doubted their existence during life and suggested that they were the result of a separation of annular fibers (35).

Despite the great debate that once surrounded this area, little attention is given to it in today's literature, although more than ever it is a surgical consideration; this space is often disturbed during discectomy. The UP can be appreciated at the point where the superior edge of the VB begins to curve upward. In our measurements, only 0 to 3 mm separates the rostral tip of the UP from the VB before discectomy (Table 2). After discectomy and distraction, this space opens to a width of up to 6 mm (Table 3). With distraction, the nerve root, which is often visible rostral to the UP, and the VA are more vulnerable to injury in the distracted disc space through the opening of the joint of Luschka (Fig. 5). Controversy regarding normal mechanics of the spine continues. Our study was undertaken not to address the biomechanics of the spine but to focus on important surgical anatomy. However, when the interspaces were distracted, a degree of biomechanics entered into the picture. To better understand the biomechanics of the cervical interspace, specimens, while still fresh, would need to be preserved by deep freezing to  $-20^{\circ}\text{C}$  (16). Studies have demonstrated that deep freezing does not significantly alter



FIGURE 7. Longus colli muscle (right side) has been removed to expose the C.P.s.

the biomechanical characteristics of bone, annulus, ligament, or the motion segment as a single unit (16, 24, 31, 41, 47).

Our study used formalin-fixed specimens, which are not suitable for biomechanical studies because formalin-fixed techniques render the soft tissue structures, such as ligament, muscle, and annulus, stiffer and less elastic than does deep freezing; therefore, the measurements obtained in this study with distraction may be conservative and the window of injury may be greater than reflected in our results.

Several factors indicate that sharp dissection should be performed in a lateral to medial direction to help avoid injury. Instruments often can pass inadvertently through the opening between the tip of the UP and the vertebral endplate. The distance from the tip of the UP to the VA averaged 0.8 mm at C2-C3 and 1.6 mm at C4-C5. Therefore, when the UP is identified, it is important to appreciate that the VA is intimately associated with the lateral border of the UP (Fig. 7). Caution should be exercised when the UP is removed in an attempt to remove osteophytes. In a review of 10 cases of VA injury, Smith et al. (44) found that the use of a high-powered drill laterally was the most frequent cause of VA injury.

The best management of an iatrogenic VA injury should occur, is controversial. Tew and Mayfield (46), de los Reyes et al. (12), Goheke et al. (18), Pfeifer et al. (36), and Golfinos et al. (17) advocate direct exposure and repair, whereas simple tamponade is recommended by other sources (12, 17, 18, 36, 44, 46). Exposure laterally involves further dissection of the longus colli muscle and bone removal of both the CP and the UP.

Traumatic vertebral arteriovenous fistula is a rare condition. Cosgrove and Theron (11) reported two cases of vertebral arteriovenous fistula after anterior spine surgery. The osteophylectomies were plagued by troublesome bleeding, which was treated with hemostatic packing. Occlusion of the fistula was performed with detachable balloons.

Approaches in a noniatrogenic traumatic injury to the VA have involved ligation of the artery (18, 43). A consideration in the older population undergoing procedures for degenerative cervical disease is arteriosclerosis of the vertebral system; however, the possibility that tamponade or ligation of

the VA could further compromise an already tenuous posterior circulation must be considered.

The surgeon must keep in mind that the UP is an important bony landmark, and with increasing age it often enlarges and flattens, with loss of its sharp, bony characteristics (3). An understanding of this underappreciated, yet often visited, bony prominence can help avoid injuries.

The height of the distracted disc space is important if arthrodesis is performed. As noted in *Table 3*, the interspace can accommodate, with only minor drilling, a bone graft of 10 mm. This size graft is desirable in most cases because of the loss of graft height during the bone maturation period.

The AP diameter (depth) of the disc space was the shortest at C2-C3 (17.9 mm) and the greatest at C6-C7 (20.8 mm). The depth clearly increases in a caudal direction. To reach the posterior longitudinal ligament, more disc material is removed. This diameter is always measured when any fusion or implant is performed. A helpful method to use is to counter-sink the implant 2 mm and to maintain 5 mm between the implant and the dura.

Advances in radiological imaging, such as computed tomography and magnetic resonance imaging, may help in identifying anomalous or malpositioned vascular and/or bony structures and, thereby, reduce the incidences of intra-operative mishaps.

## CONCLUSION

This study of the anatomy of the anterior cervical spine was performed using formalin-fixed cadaver specimens. As with any such study, variability of some measurements may be because of spondylitic changes, as well as age and body size. Nevertheless, these measurements provide the surgeon with a starting point to address bony architecture surrounding targeted soft tissue. The surgeon should not embark on surgery of the anterior cervical spine without a firm understanding of the hidden vascular and bony anatomy and a knowledge of the changes that occur during dissection. Although avoiding unfortunate injury is not always possible, an understanding of the location and relations among the anatomic features is the only safeguard against unwarranted damage.

## ACKNOWLEDGMENTS

We thank Patrick W. Lank, Ph.D., Department of Anatomy, University of Arkansas for Medical Sciences, Little Rock, Arkansas, and Rume Hilawala, Ph.D., Department of Anatomy, West Virginia University, Morgantown, West Virginia, for assistance in procuring the anatomy specimens. We are indebted to Paulin Vagoun and Ron M. Tribell for the artwork. We appreciate the entrance of B. Lee Upton, Ph.D., through the editing of this article. Finally, we thank Vijay K. Goel, Ph.D., Department of Biomedical Engineering, University of Iowa, Iowa City, Iowa, for advice concerning biomechanics.

Received, April 7, 1997.

Accepted, April 17, 1998.

Reprint requests: F. Glenn Pait, M.D., Department of Neurosurgery, University of Arkansas for Medical Sciences, 4301 West Markham Street, 5404 807, Little Rock, AR 72205.

## REFERENCES

1. Aray LB. The skeletal system. In Aray LB (ed): *Developmental Anatomy: A Textbook and Laboratory Manual of Embryology*. Philadelphia, W.B. Saunders Co., 1925, pp 206-222.
2. Bailey RW, Badgley CE: Stabilization of the cervical spine by anterior fusion. *J Bone Joint Surg Am* 42:565-594, 1960.
3. Bland JH: New anatomy and physiology with etical and historical implications. In Bland JH (ed): *Disorders of the Cervical Spine: Diagnosis and Medical Management*. Philadelphia, W.B. Saunders Co., 1994, ed 2, pp 71-91.
4. Bohler J, Gaudernak E: Anterior plate stabilization for fracture-dislocations of the lower cervical spine. *J Trauma* 20:203-205, 1980.
5. Bremer AM, Nguyen TQ: Internal metal plate fixation combined with anterior interbody fusion in cases of cervical spine injury. *Neurosurgery* 12:649-653, 1983.
6. Cabanela ME, Ebersold MJ: Anterior plate stabilization for bursting loadrop fractures of the cervical spine. *Spine* 13:888-892, 1988.
7. Caspar W, Barbier DD, Klara PX: Anterior cervical fusion and Caspar plate stabilization for cervical trauma. *Neurosurgery* 25:491-502, 1989.
8. Caye AJE, Griffiths JD, Whiteley MM: Osteo-arthritis deformans of the Luschka joints. *Lancet* 245:176-179, 1955.
9. Clemente CD (ed): Osteology. In *Gray's Anatomy*. Philadelphia, Lea & Febiger, 1985, ed 13 [American], pp 114-328.
10. Cloward RB: The anterior approach for removal of ruptured cervical discs. *J Neurosurg* 15:602-617, 1958.
11. Cosgrove GR, Theron J: Vertebral arteriovenous fistula following anterior cervical spine surgery. *J Neurosurg* 66:297-299, 1987.
12. de los Reyes RA, Moser FC, Sach OP, Bishm FJ: Direct repair of an extra-cranial vertebral artery pseudoaneurysm: Case report and review of the literature. *Neurosurgery* 26:528-533, 1990.
13. Dvorak J, Sandler A: Historical perspective. Hubert von Luschka, pioneer of clinical anatomy. *Spine* 19:2475-2482, 1994.
14. Flynn EB: Neurologic complications of anterior cervical interbody fusion. *Spine* 7:536-539, 1982.
15. George B, Laurian C: *The Vertebral Artery, Pathology and Surgery*. New York, Springer-Verlag, 1987.
16. Goel VK, Weinstein JN, Patwardhan AG: Biomechanics of intact ligamentous spine. In Goel VK, Weinstein JN (eds): *Biomechanics of the Spine: Clinical and Surgical Perspectives*. Boca Raton, CRC Press, Inc., 1990, pp 97-156.
17. Gofinos JG, Dickman CA, Zabramski JM, Sonntag VKH, Spetzler RF: Repair of vertebral artery injury during anterior cervical decompression. *Spine* 19:2552-2556, 1994.
18. Gräcke P, Scalfani S, Phillips T, Goldstein A, Scales T, Duncan A: Vertebral artery injury: Diagnosis and management. *J Trauma* 27:856-865, 1987.
19. Graham H: Complications of cervical spine surgery. *Spine* 14:1046-1050, 1989.
20. Guntz F: Die jugendlichen unfälle als Ursache von Körperbehinderung und ihre derbütung. *Z Kruppelfurs* 30:84-93, 1937.
21. Häglund E: Die Bedeutung der cervikalen diskus degeneration für die entstehung von verengungen der foramina intervertebralia (eine anatomische untersuchung) *Acta Radiol (Stockh)* 23:568-580, 1942.
22. Hardy RW: Complication of anterior cervical surgery. In Tarlov ED (ed): *Complications of Spinal Surgery*. Park Ridge, American Association of Neurological Surgeons, 1991, pp 85-94.
23. Henderson MS: Tuberculosis of the spine: End-results of operative treatment. *Surg Gynecol Obstet* 24:600-604, 1917.
24. Hirsch C, Galante J: Laboratory conditions for tensile tests in annulus fibrosus from human intervertebral discs. *Acta Orthop Scand* 36:148-162, 1967.
25. Hodgson AR, Stock EE: Anterior spinal fusion: A preliminary communication on the radical treatment of Pott's disease and Pott's paraplegia. *Br J Surg* 54:266-275, 1956.
26. Horwitz NH, Rizzoli HV: Herniated intervertebral discs and spinal stenosis. In Horwitz NH, Rizzoli HV (eds): *Postoperative Complications of Extracranial Neurosurgery*. Baltimore, Williams & Wilkins, 1987, pp 30-98.
27. Ito H, Tsuchiya S, Asami C: A new radical operation for Pott's disease. *J Bone Joint Surg Am* 16:499-515, 1934.
28. Jenkins JA: Spondylolisthesis. *Br J Surg* 24:80-85, 1937.
29. Krøgdahl E, Torgersen O: Die unco-vertebralgelenke und die arthrosis deformans unco-vertebralis. *Acta Radiol (Stockh)* 21:231-262, 1940.
30. Luschka H: *Die Haltungselenke des Menschlichen Korper*. Berlin, Reimer, 1858.
31. McCormick WE: Trauma. In Rosenberg RN (ed): *The Clinical Neurosciences*. New York, Churchill-Livingstone, 1983, pp 214-244.
32. Müller W: Transperitoneale freilegung der wirbelsäule bei tuberkulöser spondylitis. *Deutsche Zeitschrift für Chirurgie* 85:28, 1906 (abstr).
33. Orozco R, Llovet J: Osteosintesis en las fracturas del raquis cervical. *Rev Orthop Traumatol* 14:285-288, 1970.
34. Panjabi MM, Krag M, Summers D, Videman T: Biomechanical time tolerance of fresh cadaveric human spine specimens. *J Orthop Res* 3:292-300, 1985.
35. Payne JF, Spillane JD: The cervical spine: An anatomicopathological study of 70 specimens (using a special technique) with particular reference to the problem of cervical spondylosis. *Brain* 80:571-597, 1977.
36. Pfister BA, Freedberg SR, Jewell EK: Repair of injured vertebral artery in anterior cervical procedures. *Spine* 19:1471-1474, 1994.
37. Rathcke H: Zur normalen und pathologischen anatomic der halswirbelsäule. *Deutsche Zeitschrift für Chirurgie* 242:122-137, 1934 (abstr).
38. Robinson RA, Smith GW: Anterolateral cervical disc removal and interbody infusion for cervical disc syndrome. *Bull John Hopkins Hosp* 96:223-224, 1955.
39. Schneider RC: Treatment of cervical spine disease. In Schneider RC, Kahn EA, Crosby EC, Ezen JA (eds): *Correlative Neurosurgery*. Springfield, Charles C Thomas, 1982, ed 3, pp 1094-1174.
40. Schweighofer E, Passler IM, Wildburger R, Hofer HP: Interbody fusion of the lower cervical spine: A dangerous surgical method. *Langenbecks Arch Chir* 377:295-299, 1992.
41. Sedlm E, Hirsch C: Factors affecting the determination of the physical properties of femoral cortical bone. *Acta Orthop Scand* 37:39-48, 1966.
42. Senegas J, Ganzere JM: Plaidoyer pour la chirurgie antérieure dans la traitement des traumatismes graves des cinq dernières vertèbres cervicales. *Rev Chir Orthop* 62(Suppl 2):123-128, 1976.

43. Shjatan A, Zervas NT: Consequence of ligation of the vertebral artery. *J Neurosurg* 36:447-450, 1972
44. Smith MD, Emery SE, Dudley A: Vertebral artery injury during anterior decompression of the cervical spine. *J Bone Joint Surg Br* 75:410-415, 1993.
45. Terry RJ: Osteology, in Schaefer JP (ed): *Morris' Human Anatomy: A Complete Systemic Treatise*. Philadelphia, The Blakiston Co., 1942, pp 77-265.
46. Tew JM, Mayfield FH: *Complications of surgery of the Anterior Cervical Spine, Clinical Neurosurgery*. Baltimore, Williams & Wilkins, 1976, pp 424-434.
47. Tkaczuk H: Tensile properties of human lumbar longitudinal ligaments. *Acta Orthop Scand Suppl* 115:8-69, 1968.
48. Trolard P: Quelques articulations de la colonne vertebrale. *Int Monatschr F Anat Physiol* 10:1-11, 1893.
49. Wilkinson MC: Curettage of tuberculous vertebral disease in the treatment of spinal cysts. *Proc R Soc Med* 43:114-115, 1950.
50. Wiltberger BR: Resection of vertebral bodies and bone-grafting for chronic osteomyelitis of the spine. *J Bone Joint Surg Am* 54:215-218, 1932.

## COMMENTS

Anterior cervical spine surgery is one of the more common spine surgeries; however, the detailed surgical anatomy of the cervical spine has not been used. The authors provide information that will serve all surgeons who operate in this area.

I think the authors highlighted many important measurements; however, the most important was the distance from the uncinate process (UP) to the nearby vertebral artery, which was from 0.8 mm at C2-C3 to 1.6 mm at C4-C5. This measurement should be remembered when attempting to decompress the nerve root laterally from the "joint of Luschka." The measurement was taken from the anterior UP, but the distance of the posterior UP from the vertebral artery, where the decompression is performed, must be similar. In fact, knowing that the distance is minimal, it is surprising that the incidence of vertebral artery injury is as low as it is, and I agree with the authors that it is probably underreported. We believe that direct repair, if possible, is the preferred method of treatment to prevent the formation of fistula and/or aneurysms (1).

Another important measurement is the depth of the disk space, which is shortest at C2-C3 (17.9 mm) and deepest at C6-C7 (20.8 mm); if direct measurements cannot be made or are unavailable and a fusion is performed at these interspaces, the size of the bone graft must be within those limits.

Volker K.H. Sonntag  
Phoenix, Arizona

Richard G. Fessler  
Gainesville, Florida

1. Goftinos JC, Dickman CA, Zabramski JM, Sonntag VKH, Spetzler RF: Repair of vertebral artery injury during anterior cervical decompression. *Spine* 19:2555-2558, 1994.

Pait et al. provide an interesting and important anatomic contribution to our knowledge of the anatomy of the cervical spine. Four points brought out by these authors deserve special attention.

First, the distance between the medial borders of the longus colli muscles narrows remarkably at the C2-C3 level. Because of the presence of the mandible and the size and location of the trachea, discectomy at C2-C3 can be difficult under the best of circumstances. Large longus colli muscles, which are relatively medially located, can make the surgery even more difficult. Therefore, additional time spent in adequate cephalad and lateral mobilization of these muscles early in the treatment can make the subsequent discectomy procedure significantly easier.

Second, far lateral exposure of the costal processes (such as may be required for resection of a tumor) can be performed anteriorly. This requires far lateral mobilization of the longus colli muscles over several adjacent vertebral segments. Particularly as one moves cephalad in the cervical spine, this must be performed with cognizance of the relatively exposed vertebral arteries.

Third, in performing routine discectomy in the cervical spine, it is common practice to remove the disc to the level of the UP. The data of Pait et al. demonstrate that the distance between the tip of the UP and the vertebral artery can be <1 mm. Finally, Pait et al. have demonstrated that the distance between the tip of the UP and the superior adjacent vertebral body increases from approximately 3 to 6 mm with distraction. Therefore, surgeons performing aggressive lateral discectomies in a distracted cervical spine must keep in mind the close proximity of the vertebral artery to the tip of the UP, and must be aware that there is ample space between the UP and the adjacent vertebral body to allow a wayward curette or Kerrison punch access to the vertebral artery.

This anatomic analysis of the anterior approach to the cervical spine has highlighted several important surgical considerations. The information provided will be important to all neurosurgeons who perform anterior cervical surgery.