

# The Anatomy of the Atlantoaxial Complex

T. GLENN PAIT, M.D., KENAN I. ARNAUTOVIC, M.D., and  
LUIS A.B. BORBA, M.D.

Operating on the atlantoaxial complex has always posed a challenge to the surgeon because of the complex anatomy and biomechanics of this region of the spine. Recent developments and refinements of surgical techniques, which proffer better surgical outcomes for patients, require that surgeons gain a better understanding of the anatomy of this vital territory.

For instance, the satisfactory application of new methods of internal surgical fixation, using refined implants, depends on the surgeon's thorough knowledge of not only the anatomy in the immediate surgical field, but also those structures that are not visualized, including those that will not be dissected during surgery. This is certainly the case with dorsal spinal fixation procedures such as transarticular screw fixation at C1-C2, or pedicular fixation at C2. To successfully address lesions of the posterior C1-C2 complex, the surgeon must appreciate the soft tissue elements, the bony architecture, and the physiologic mechanics of all structures incorporated in this unique segment of the human vertebral column.

## ANATOMY

### The Atlas

The atlas, upon which rests the skull, is remarkable in that it lacks a body. An irregular ring, it consists of two symmetrical lateral masses that are united by the anterior and posterior arches. These lateral masses possess a superior articular pit or cavity for articulation with the occipital condyles and an inferior articular surface that meets the superior articular surface of the axis at the C1-2 joint (Fig. 1).

The lateral masses of the atlas, which are also the true lateral masses of the cervical spine, are thick, supportive elements composed of both a superior and an inferior articular pit or surface. The superior oval articular pit articulates with the occipital condyles. The inferior circular articular facies communicate

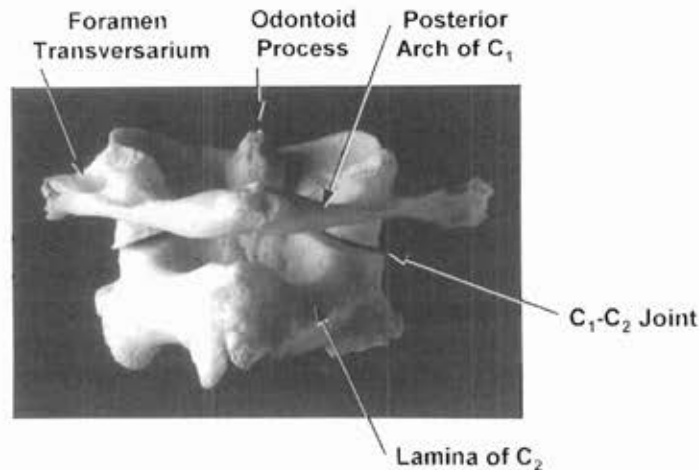


Fig. 1 The posterior aspect of the atlantoaxial bony complex.

with the superior articular surface of C2 (Fig. 2). The inferior articular surface of C1 and the superior articular surface of C2 differ from other cervical articular surfaces by being situated ventral to the exit sites of the spinal nerves.

The lateral masses give rise to the lateral process, the costal process, and the transverse process. The transverse process of C1, which extends more laterally than do the other cervical processes, is bound medially by the transverse foramen (Figs. 1 and 2).

The posterior arch of C1 unites the lateral masses and joins the median line dorsally at the posterior tubercle, which is a rudimentary spinous process. The sulcus arteriae vertebralis (groove for the vertebral artery) is situated on the cranial surface of the posterior arch at its junction with the lateral mass.<sup>1</sup> This sulcus occasionally converts into a foramen or a canal by a bony arch. A

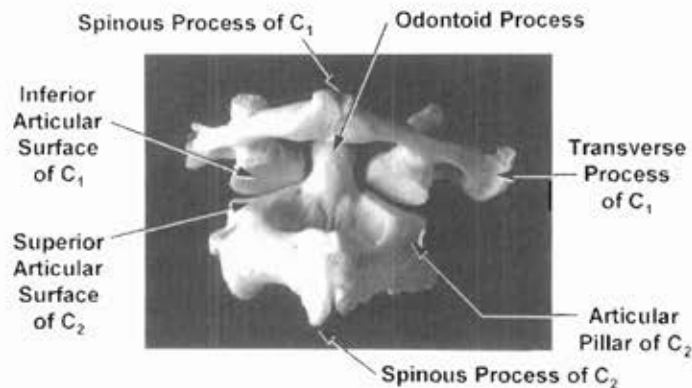


Fig. 2 The posterior aspect of the atlantoaxial complex. C2 is reflected upwards.

shallow notch for the exit of the second spinal nerve is located on the caudal surface of the posterior notch of C2. The cranial and caudal surfaces of the posterior arch furnish attachments to the ligaments that unite the atlas to the occipital bone and to C2.

### The Axis (C2)

The axis, C2, is the thickest of the cervical vertebrae that form a pivot on which the atlas rotates. The inferior articular pillar of C2 meets the superior articular pillar of C3 and conforms to the usual cervical articular mass configuration. The spinous process of C2 is a large, strong, and bifid bony structure that unites the thickened laminae. The laminae of C2 fan out laterally to the articular masses. An articular mass of C2 is composed of a superior and an inferior articular pillar. Benzel et al.<sup>2</sup> refer to the superior articular pillar as the pars interarticularis of C2. They emphasize that this structure should not be confused with the pedicle. Each articular pillar has an articular surface. The superior articular pillar of C2 is longer than other cervical pillars. The superior articular surface is unique in that it occupies positions partly on the pillar and partly on the body (Fig. 2). The pedicle of C2, which courses from the body of C2 to the dorsal surface of the articular surface of C2 (Fig. 3), is located more medially and ventrally than are other cervical spine pedicles.<sup>2,3</sup>

### The Vertebral Artery

The transverse foramen of C2 is directed very obliquely cranially and laterally (Fig. 3). The third of four segments of the vertebral artery courses through this foramen. The vertebral artery is divided into four parts: the first

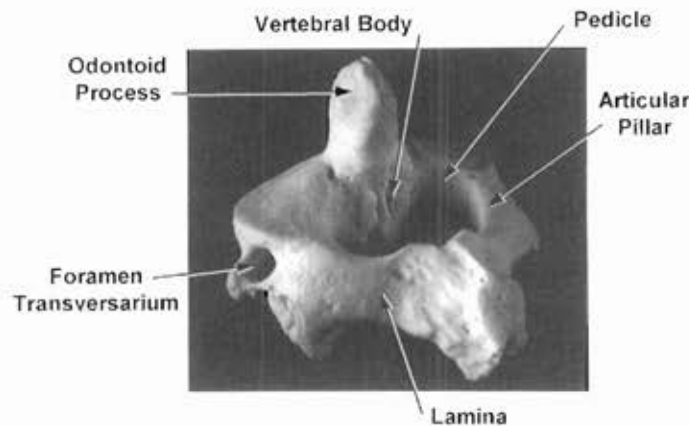
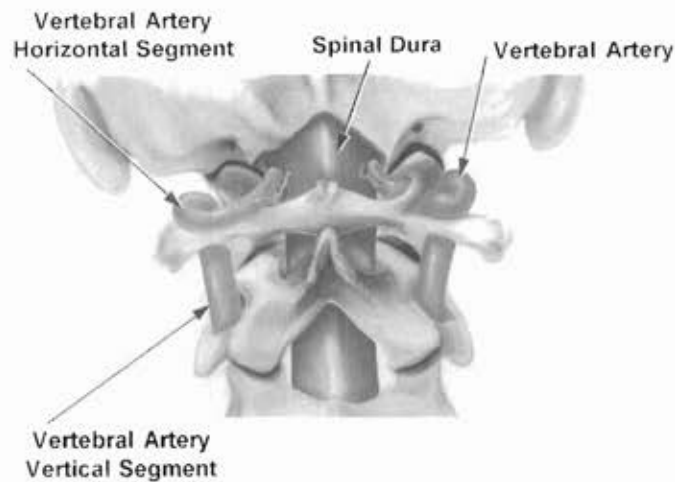


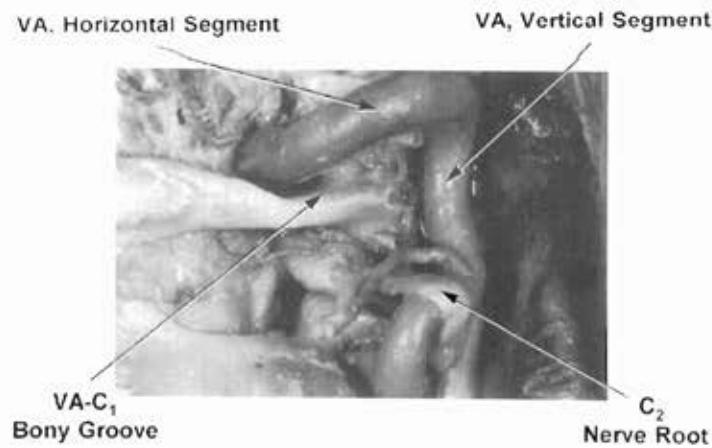
Fig. 3 The posterior aspect of the left side of C2.



**Fig. 4** Posterior view of vertebral artery (V3) and its relationship to the bony complex.

extends from its origin to the transverse process of C6; the second courses through the transverse foramen; the third, the axoatlantic segment, continues in the suboccipital region, coursing vertically then horizontally; and the fourth pierces the arachnoid to form the basilar artery with a running mate.<sup>4</sup> Fisher<sup>5</sup> classified these four segments as V1, V2, V3, and V4, respectively.

During rotation of the head, the head and atlas can turn by 35° from a neutral position, zero, to the opposite side; therefore, the axoatlantic segment (V3) must be especially elastic or contain vascular loops.<sup>6</sup> It extends from the transverse foramen of C2 to the foramen magnum (Figs. 4 and 5) and runs vertically



**Fig. 5** Posterior view of the right V3, horizontal and vertical.

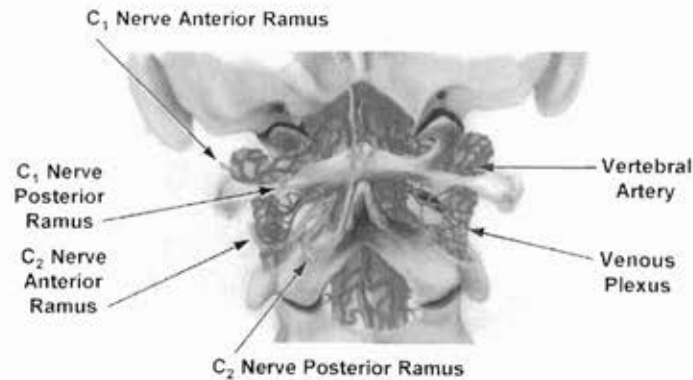


Fig. 6 Venous plexus surrounding the vertebral artery.

between C2 and C1 up to the foramen of C1; it is covered by the levator scapulae and the inferior oblique muscles. The V3 is crossed posteriorly by the anterior ramus of the C2 spinal nerve (Fig. 5). The C2 nerve is usually attached to the artery by fibrous connections. The vertical segment usually gives out a radiculomuscular artery above the anterior ramus of C2. This artery supplies the adjacent spinal cord, nerve, dura, and other surrounding structures.

In the transverse foramen of C1, the artery changes its direction from vertical to horizontal (Fig. 4). The foramen of C1 is prolonged by a transverse process that is much larger than those at other levels. This serves as a very good surgical landmark.<sup>4</sup> The artery runs around the lateral mass of the atlas in a horizontal bony groove above the posterior arch of C1 (Fig. 5). At the end of the bony groove, the artery bends forward, inward, and upward to reach the dura of the foramen magnum. The artery is hidden by a posterior atlanto-occipital membrane, a thin, fibrous layer connected at the top to the posterior margin of the foramen magnum and at the bottom to the superior border of the posterior arch of the atlas. Over the bony groove, the membrane is defective and forms, with the groove, an opening for the passage of the artery into the dura and for the exit of the first cervical spinal nerve.<sup>7</sup> The spinal nerve courses below the artery, dividing into the anterior and posterior rami (Fig. 6).

At the V3, the periosteal sheath is reinforced by the transverse and retroglonoid ligaments.<sup>10</sup> These ligaments may be ossified over the entire posterior groove; hence, this groove becomes a bony canal.<sup>1,8,9</sup> The V3 terminates at the dura and continues rostrally as the fourth, intracranial segment (V4) (Fig. 4). Throughout its course, the vertebral artery is accompanied by vertebral veins, which are densely interconnected around the V1 and form a true network or plexus around the artery (Figs. 6 and 7). Venous inflow in this network occurs from muscles, nerves, bony parts, and radicular veins.

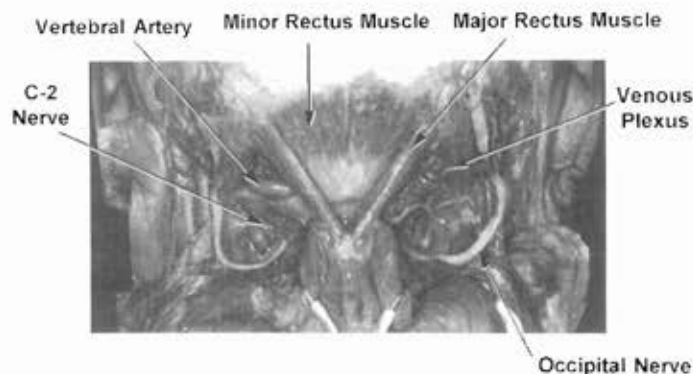


Fig. 7 The deep atlantoaxial muscles.

### The Rectus and Oblique Muscles

The short suboccipital muscles constitute the deepest muscular layer. The major rectus muscle arises from the bifid process of the axis and ascends upward and laterally to insert into the lateral half of the inferior nuchal line of the occipital bone and the area below it (Fig. 7).<sup>3,11</sup> The minor rectus muscle arises from the tubercle of the posterior arch of the atlas, ascends under the rectus major, and enters into the medial part of the inferior nuchal line and the area of the occipital bone immediately below (Fig. 7).<sup>3,11</sup> It is the only muscle that attaches to the atlas. The inferior oblique muscle arises from the spinous process of the axis and courses horizontally lateral and forward and is inserted into the lower and posterior aspects of the lateral mass of the atlas and slightly into the posterior arch (Fig. 8). The superior oblique muscle

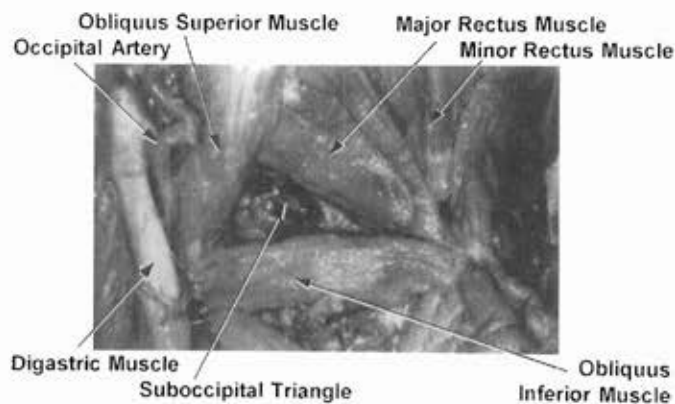


Fig. 8 The suboccipital triangle (left).

arises from the lateral mass of the atlas and the beginning of the posterior arch of C1. It diverges upward posteriorly and medially and is inserted by short tendons into the lateral third of the inferior nuchal line of the occipital bone. The rectus muscle and the superior oblique muscle draw the head backward. The rectus major and the inferior oblique muscles, when acting on one side, rotate the face toward that side.<sup>3</sup> The two oblique muscles with the rectus major muscle form a small triangular space, the suboccipital triangle (Fig. 8),<sup>3</sup> through which the dorsal division of the suboccipital (C1) nerve passes. In front of the two oblique muscles and the major rectus muscle runs the vertebral artery.

## CONCLUSION

The atlantoaxial complex occupies a relatively small place in the literature on neurosurgery and spinal surgery. Yet, any implementation of the different techniques of surgery in this area requires that the surgeon have a basic knowledge of its anatomy. An early interest in this area arose from vascular surgery, but minor importance was attributed to the vertebral artery because of its relatively infrequent pathology, deep location, and difficult access for exploration and surgery. In 1836 Sanson reported that the vertebral arteries were so hidden and inaccessible that they were beyond the reach of surgery.<sup>4</sup> However, trauma forced surgeons to address the vertebral artery, demanding that they understand the bony architecture of its confining anatomy.

With the advent of the microscope, the ability to appreciate and expose the vertebral artery and to address the vascular lesions and tumors around it has come of age. The vertebral artery is intimately associated with bony structures that can be dissected away. In the past these exposure techniques have posed the problem of vertebral column instability. However, advancements in engineering and technology have produced an entirely new generation of internal fixation devices that allow for more aggressive surgical intervention for lesions of the atlantoaxial complex. Surgeons have been prompted to reevaluate traditional methods of surgery. Among the new techniques that surgeons are now implementing are the transcondylar approach, the transarticular pillar approach, and transarticular screw fixation techniques.

Undoubtedly, these new methods of posterior exposure and osteosynthesis, often using plates and screws, have advanced the surgical management of pathology and instability of the atlantoaxial complex. The contemporary spinal surgeon must have a thorough understanding of the appropriate segmental and regional anatomy, without which a safe and successful surgical procedure is less likely to be the final outcome.

## ACKNOWLEDGMENTS

The authors thank Ms. Amy Keeland for preparing the manuscript and B. Lee Ligon, Ph.D., for editing it. We are grateful to Mr. Ron M. Tribell for his artwork.

## REFERENCES

1. Terry RJ. Osteology. In: Schaeffer JP, ed. *Morris' Human Anatomy*. Philadelphia: Blakiston, 1942, pp 77-265.
2. Benzel EC, Hart BL, Ball PA, Baldwin NG, Orrison WW, Espinosa M. Fractures of the C2 vertebral body. *J Neurosurg* 81:206-212, 1994.
3. Grant JCB. The musculature. In: Schaeffer JP, ed. *Morris' Human Anatomy*. Philadelphia: Blakiston, 1942, pp 377-581.
4. George B, Laurian C. *The Vertebral Artery, Pathology and Surgery*. New York: Springer-Verlag, 1987.
5. Fisher CM. The pathology and pathogenesis of the intracerebral hemorrhage. In: Fields WS, ed. *Pathogenesis and Treatment of Cerebrovascular Disease*. Springfield, IL: Charles C. Thomas, 1961.
6. Lang J, Kessler B. About the suboccipital part of the vertebral artery and the neighboring bone-joint and nerve relationships. *Skull Base Surg* 1:64-71, 1991.
7. Gray H. *Anatomy of the Human Body*, 30th American ed., Clemente CD, ed. Philadelphia: Lea & Febiger, 1985, pp 329-428.
8. Lang J. Craniocervical region, osteology and articulations. *Neuro-orthopedics* 1:67-92, 1986.
9. Radojevic S, Negovanovic B. La gouttière et les anneaux osseux de l'artère vertébrale de l'atlas. *Acta Anat* 55:186-194, 1963.
10. Franke JP, Dimarino V, Pannier M, Argenson C, Liberson C. The vertebral arteries. The V3 atlanto-axoidal and V4 intracranial segments collaterals. *Anatomia Clinica* 2:229-242, 1981.
11. Lang J. Craniocervical region, surgical anatomy. *Neuro-orthopedics* 3:1-26, 1987.