

# Anterior Clinoid Metastasis Removed Extradurally: First Case Report

Mirza Pojskić<sup>1</sup> Blazej Zbytek<sup>2,3</sup> Kenan I. Arnautović<sup>4,5</sup>

<sup>1</sup>Department of Neurosurgery, Philipps University of Marburg, Marburg, Germany

<sup>2</sup>Department of Pathology and Laboratory Medicine, Center for Adult Cancer Research, University of Tennessee Health Science Center, Memphis, Tennessee, United States

<sup>3</sup>Pathology Group of the MidSouth, Memphis, Tennessee, United States

<sup>4</sup>Semmes Murphey Neurologic & Spine Institute, Memphis, Tennessee, United States

<sup>5</sup>Department of Neurosurgery, University of Tennessee Health Science Center, Memphis, Tennessee, United States

Address for correspondence Kenan I. Arnautović, MD, PhD, Semmes Murphey Neurologic & Spine Institute, 6325 Humphreys Blvd., Memphis, TN 38120, United States (e-mail: kenanarnaut@yahoo.com).

J Neurol Surg Rep 2018;79:e55–e62.

## Abstract

**Background** We report a case of isolated metastasis on the anterior clinoid process (ACP) mimicking meningioma.

**Clinical Presentation** A 58-year-old male presented with headaches, right-sided visual disturbances, and blurred and double vision. The cause of double vision was partial weakness of the right III nerve, resulting from compression of the nerve by “hypertrophied” tumor-involved right anterior clinoid. Medical history revealed two primary malignant tumors—male breast cancer and prostate cancer (diagnosed 6 and 18 months prior, respectively). The patient was treated with chemotherapy and showed no signs of active disease, recurrence, or metastasis. Postcontrast head magnetic resonance imaging (MRI) showed extra-axial well-bordered enhancing mass measuring 1.6 × 1.1 × 1 × 1 cm (anteroposterior, transverse, and craniocaudal dimensions) on the ACP, resembling a clinoidal meningioma. Extradural clinoidectomy with tumor resection was performed via right orbitozygomatic pretemporal skull base approach. Visual symptoms improved. Follow-up MRI showed no signs of tumor residual or recurrence.

**Conclusion** This is the first case report of a metastasis of any kind on ACP. Metastasis should be included as a part of the differential diagnosis of lesions of the anterior clinoid. Extradural clinoidectomy is a safe and effective method in the treatment of these tumors.

## Keywords

- ▶ anterior clinoid process
- ▶ extradural clinoidectomy
- ▶ metastasis
- ▶ anterior clinoid metastasis
- ▶ case report

## Background and Importance

We report a first case of isolated metastasis on the anterior clinoid process (ACP) mimicking a meningioma, which should be added to the differential diagnosis of the processes of ACP. The most common lesions of the anterior clinoid

process are meningiomas.<sup>1,2</sup> There are 11 different pathological entities described so far on the ACP other than meningioma (▶ **Table 1**).<sup>3–33</sup>

Clinoidectomy is the key element of the surgical treatment of neoplastic lesions of the ACP. It was developed initially as an intradural technique for approach to internal

received  
September 6, 2017  
accepted after revision  
April 10, 2018

DOI <https://doi.org/10.1055/s-0038-1655773>.  
ISSN 2193-6358.

© 2018 Georg Thieme Verlag KG  
Stuttgart · New York

License terms



**Table 1** Nonmeningioma pathology of the anterior clinoid process

Nonmeningioma pathology of the ACP	Author and year	Symptoms	Treatment and outcome
Mucocele 21 cases	Nundkumar et al, 2012 <sup>24</sup>	Sudden painless loss of vision	Endoscopic transnasal approach, complete recovery
	Johnson et al, 1986 <sup>18</sup>	Retrobulbar pain with loss of vision	Pterional approach; incomplete recovery
	Schwaighofer et al, 1989 <sup>27</sup>	Retro-orbital pain with loss of vision	Frontal craniotomy, complete recovery
	Dunya et al, 1996 <sup>11</sup>	Double vision	Endoscopic transsphenoidal, subjective improvement
	Garaventa et al, 1997 <sup>13</sup>	Retro-orbital pain with loss of vision	Endoscopic transnasal, complete recovery
	Chou et al, 1999 <sup>8</sup>	Progressive loss of vision	Supraorbital craniotomy, complete recovery
	Chung et al, 1999 <sup>9</sup>	Headache, diplopia	Pterional approach, slight recovery with light perception
	Lim et al, 1999 <sup>21</sup>	Diplopia, III nerve palsy	Frontotemporal orbitozygomatic approach, recovery of III nerve palsy
	Hejazi et al, 2001 <sup>14</sup>	Ophthalmoplegia, visual loss	Transnasal, complete recovery
	Righini et al, 2006 <sup>26</sup>	Monocular blindness	Endoscopic, complete recovery
	Deshmukh and DeMonte, 2007 <sup>10</sup>	Blind spot	Conservative treatment with oral antibiotics for sinusitis, complete recovery
	Thurtell et al, 2007 <sup>28</sup>	Painful visual loss	Pterional approach, no recovery
	Vaphiades et al, 2007 <sup>31</sup>	Painless visual loss	Endoscopic transnasal, slight recovery
	Kwon et al, 2009 <sup>20</sup>	Sudden onset of blurry vision	Transnasal, slight recovery
	Arnavielle et al, 2010 <sup>4</sup>	Painful optic neuropathy	Endoscopic, complete recovery
	Chagla et al, 2010 <sup>5</sup>	Headache, visual loss	Supraorbital craniotomy, slight recovery
	Forer et al, 2010 <sup>12</sup>	Unilateral ophthalmoplegia, eye redness	Image-guided endoscopic, complete recovery
	Moisseiev et al, 2013 <sup>23</sup>	Visual loss	Surgery, not specified
	Wang et al, 2013 <sup>32</sup>	Retro-orbital pain, double vision, III, IV, VI nerve palsy	Pterional approach, incomplete recovery
	Aoyama et al, 2014 <sup>3</sup>	Headache, visual loss	Craniotomy (not specified), slight improvement
Hopf-Jensen et al, 2014 <sup>17</sup>	III nerve palsy, diplopia	Pterional approach, intradural clinoidectomy, complete recovery	
Cavernous hemangioma 2 cases	Mansour et al, 2017 <sup>22</sup>	Incidental finding	Pterional approach, no complications
	Yamashita et al, 2006 <sup>33</sup>	Headache, visual impairment	Pterional approach, complete recovery
Isolated fibrous dysplasia of the ACP 1 case	Chang, 2009 <sup>6</sup>	One-sided blindness	Extradural clinoidectomy via pterional approach in "no drill" technique, no recovery
Pilocytic astrocytoma 1 case	Hong et al, 2014 <sup>16</sup>	One-sided visual loss	Frontotemporal craniotomy, improved vision

**Table 1** (Continued)

Nonmeningioma pathology of the ACP	Author and year	Symptoms	Treatment and outcome
Inflammatory pseudotumor 1 case	Kasliwal et al, 2008 <sup>19</sup>	Visual diminution and proptosis	Surgical decompression, high-dose steroids, complete recovery
Pyocele 1 case	O'Donnell et al, 2013 <sup>25</sup>	Fever, decreased vision, III and VI nerve palsy	Intravenous antibiotics followed by surgery, approach not specified, complete recovery
Dermoid cyst 1 case	Higgins and Schimdt, 1996 <sup>15</sup>	Not specified	Stereotactic biopsy followed by craniotomy and resection, not specified
Necrotizing sarcoid granuloma 1 case	Tobias et al, 2003 <sup>29</sup>	Left visual deterioration and proptosis	Frontotemporal craniotomy with extradural removal of the ACP; corticosteroid therapy, visual improvement, stable disease
Bony protuberance of the ACP leading to aneurysm of the ICA due to trauma	Cheong et al, 2011 <sup>7</sup>	Severe headache after craniofacial injury	Clipping and wrapping of the traumatic aneurysm, complete recovery
DAVF draining into the superficial middle cerebral vein 1 case	Ushikoshi et al, 2013 <sup>30</sup>	Sudden onset of altered consciousness	Frontotemporal craniotomy, clipping of the DAVF, complete recovery
Metastasis of the breast cancer 1 case	Pojskić et al (this case)	Blurry and double vision on the right side	Orbitozygomatic pretemporal craniotomy, extradural clinoidectomy, complete recovery

Abbreviations: ACP, anterior clinoid process; DAVF, dural arteriovenous fistula; ICA, internal carotid artery.

carotid artery and ophthalmic aneurysms.<sup>34,35</sup> It can be performed either intra- or extradural. Total clinoidectomy has been advocated in all neoplastic lesion of the clinoid, since at least a quarter of patients with radiographically negative imaging of ACP will have tumor involvement on pathological analysis.<sup>36</sup>

## Clinical Presentation

Appropriate consent was obtained from the patient.

### Symptoms

A 58-year-old male presented with headaches, right-sided blurred vision, and double vision. The cause of double vision was partial weakness of the right III nerve resulting from compression of the nerve by “hypertrophied” tumor-involved right anterior clinoid. His previous medical history revealed existence of two primary malignant tumors: breast cancer (diagnosed 6 months prior) and prostate cancer (diagnosed 18 months prior). The patient was under treatment with chemotherapy due to breast cancer and showed no signs of active disease.

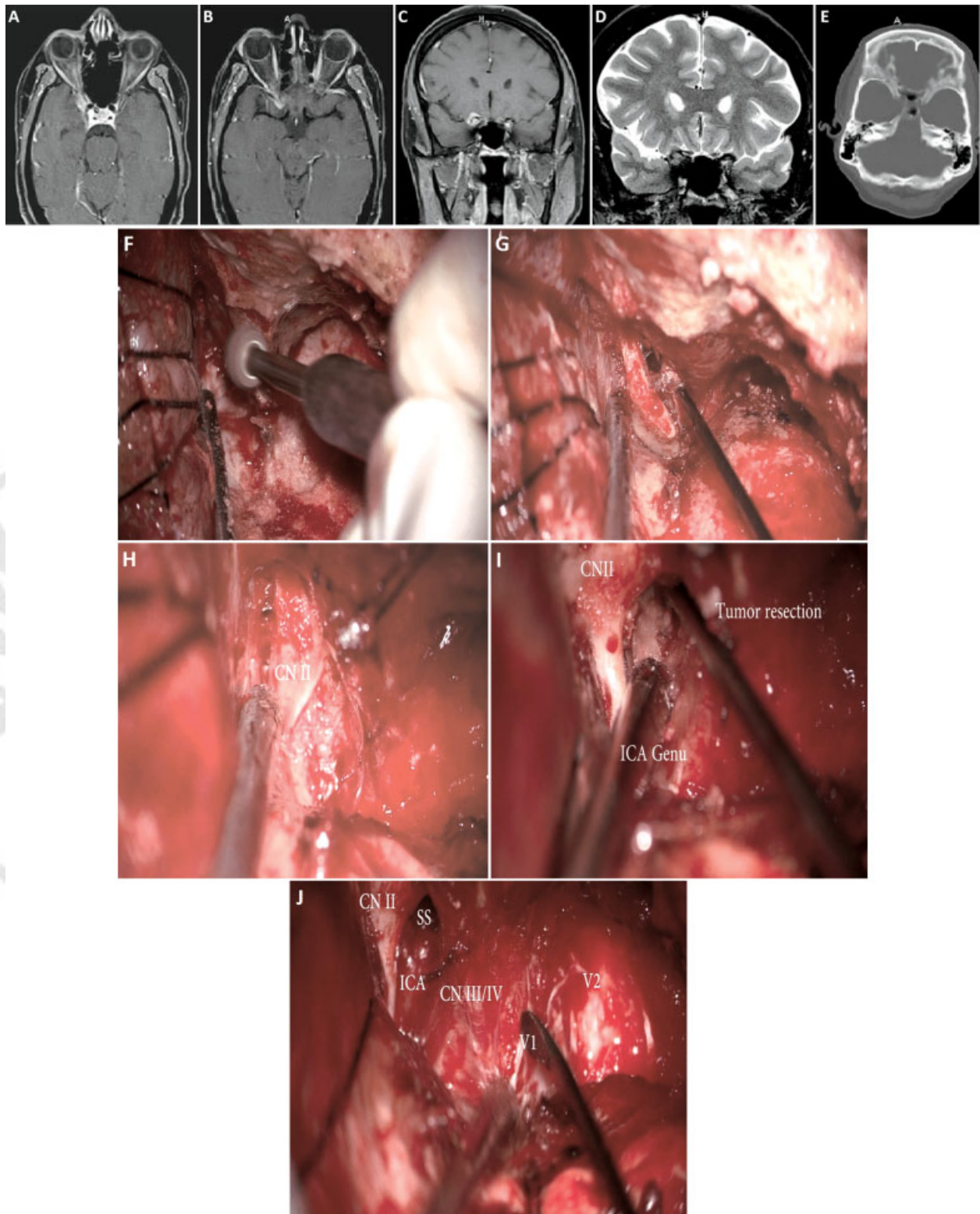
### Magnetic Resonance Imaging Presentation

Postcontrast magnetic resonance imaging (MRI) of the head showed an extra-axial, well-bordered enhancing mass mea-

suring  $1.6 \times 1.1 \times 1.1$  cm of the ACP with involvement of the right optic canal (OC) along its superior lateral margin with dural tail typical for a meningioma. No other intracranial lesions were present. Meningioma was considered a primary differential diagnostic possibility preoperatively (►Fig. 1). The surgery was indicated due to symptomatic lesion, which progressively affected the vision on the right eye and to obtain the histological diagnosis.

### Surgical Technique

Extradural clinoidectomy with tumor resection was performed by the senior author (K.I.A.). The details of the orbitozygomatic pretemporal approach have been previously described.<sup>1,2,37-39</sup> Skin incision and preparation of the temporalis muscle and orbitozygomatic craniotomy with drilling of the sphenoid ridge were performed in usual manner.<sup>37</sup> The superior orbital fissure (SOF) was identified and unroofed, removing the bone overlying the superolateral margin of the SOF with rongeurs and a diamond burr. The meningo-orbital artery was coagulated and divided. Frontobasal and temporal dura were retracted with dural tack up sutures. Dura propria of the temporal lobe was peeled off from the SOF and the anteromedial aspect of the lateral wall of the cavernous sinus, exposing the third and the fourth cranial nerve as well as V1 and V2 of the fifth cranial nerve. Intraoperatively, the right III nerve was compressed by the hypertrophied



**Fig. 1** Preoperative postcontrast magnetic resonance imaging (MRI) of the brain. (A) T1-weighted postcontrast axial view demonstrating a contrast-enhancing lesion on the right anterior clinoid process. (B) T1-weighted postcontrast axial view. (C) T1-weighted postcontrast coronal view, lesion on the right clinoid process resembling a clinoidal meningioma. (D) Preoperative T2-weighted coronal MRI of the brain showing anterior clinoid involved by tumor adjacent to right optic nerve. (E) Computed tomography (CT) scan of the head, axial view. (F) Intraoperative microsurgical drilling of the right anterior clinoid. (G) Microsurgical dissection of the clinoid from periorbita. (H) Tumor inside the clinoid below the right optic nerve (labeled CN II). (I) Resection of the tumor extending into the right sphenoid sinus below the right optic nerve (CN II). Note also the right internal carotid artery (ICA) genu. (J) Microsurgical picture after resection of the tumor-involved right anterior clinoid. Please note the CN II optic nerve, ICA genu, III, IV, V1, and V2 nerves, and sphenoid sinus (SS) after removal of the tumor.

tumor-involved anterior clinoid, but there was no evidence of dural or cavernous sinus tumor involvement.

The OC was then unroofed from a lateral to medial direction by using a 2-mm diamond burr with constant-cooling irrigation.<sup>40</sup> The tumor was involving the right anterior clinoid. The dorsal cortex of the clinoid was preserved and the tumor was involved in the central portion, penetrating ventrally and medially toward the sphenoid sinus. The opening of the sphenoid sinus was thusly done to ensure complete tumor resection and later obliterated with a small piece of muscle. Also, the third root of the ACP, the optic strut, was drilled off. During this procedure, constant awareness was maintained to protect the optic nerve, the carotid artery, and the oculomotor nerve with reference to the ACP. After removing the tumor that infiltrated the ACP, it was sent for histological analysis (►Fig. 1f–j).

### Pathohistology

Pathohistological report showed the diagnosis of the metastasis of the known infiltrating ductal carcinoma of the breast (►Fig. 2).

### Follow-Up

The postcontrast MRI showed no signs of the residual tumor (►Fig. 3). Blurred vision improved and double vision resolved completely. The patient continued to receive che-

motherapy for infiltrating ductal carcinoma of the breast by his oncologist. Also, radiation treatment was initiated.

## Discussion

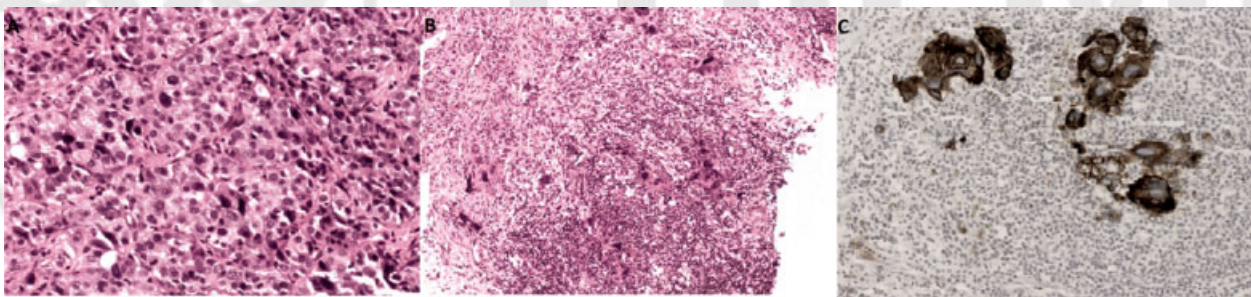
A literature review of the past 30 years using the PubMed database did not display any results for metastasis of the clinoid process. The most common lesions of ACP are meningiomas. There were more than 20 studies that included patients with surgically treated meningiomas of the ACP.<sup>1,2,29,41–58</sup> The second most common lesion of the ACP is mucocele.<sup>24</sup> ►Table 1 provides the overview of isolated non-meningioma lesions of the ACP reported so far in the literature.

### Magnetic Resonance Imaging Presentation

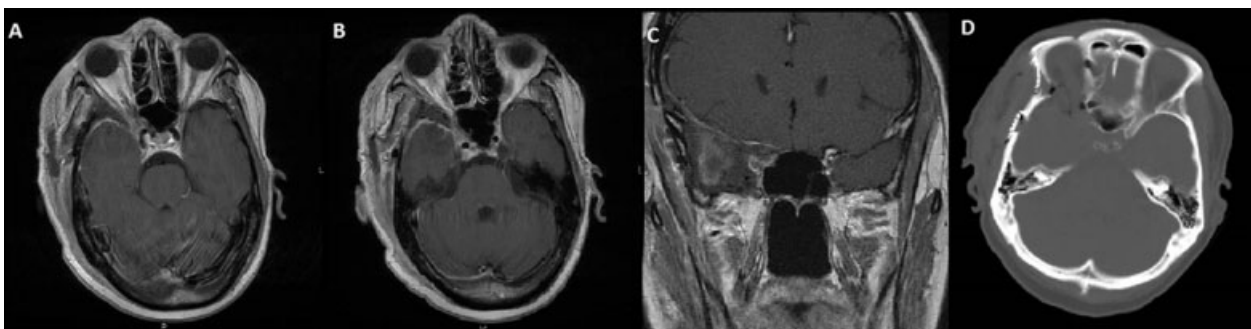
Meningiomas demonstrate homogeneous enhancement on post-contrast MRI.<sup>59</sup> Generally, there are several lesions that can mimic meningiomas, which usually present with pseudo-dural tail: breast cancer metastasis,<sup>60</sup> cavernous hemangiomas,<sup>22,61</sup> dural plasmocytoma,<sup>62,63</sup> large capillary hemangioma,<sup>64</sup> carcinoid tumor metastasis,<sup>65</sup> pilocytic astrocytoma,<sup>16</sup> liposarcoma,<sup>66</sup> and metastatic thyroid carcinoma.<sup>67</sup>

### Breast Cancer and Brain Metastases

Breast cancer represents the second most frequent cause of brain metastases, occurring in 10 to 16% of patients.<sup>68</sup>



**Fig. 2** Pathohistology specimens. (A) Tumor in the breast. Tumor consists of highly pleomorphic epithelial cells and corresponds to infiltrating ductal carcinoma of breast, poorly differentiated (Nottingham combined grade III). Hematoxylin and eosin (H&E). Magnification 200 × . (B) Tumor in clinoid bone. Tumor consists of highly pleomorphic epithelial cells in desmoplastic stroma. H&E. Magnification 100 × . (C) Tumor in clinoid bone. Tumor cells are strongly cytokeratin 7 positive. Cytokeratin 7 immunostaining. Magnification 200 × .



**Fig. 3** Postoperative postcontrast magnetic resonance imaging (MRI) of the brain. (A) T1-weighted postcontrast axial view demonstrating a complete resection of the metastasis. (B) T1-weighted postcontrast axial view. (C) T1-weighted postcontrast coronal view, complete resection of the anterior clinoid. (D) Computed tomography (CT) scan of the head, axial view, demonstrating complete removal of the anterior clinoid process.

Subgroups of patients with triple-negative and human epidermal growth factor receptor 2 (HER2)-positive breast cancer have an increased risk of developing brain metastases.<sup>69</sup> Surgical resection of the brain metastasis is an important treatment option in patients with single or few ( $\leq 3$ ) lesions.<sup>70–72</sup> However, the breast cancer metastasis or any other metastasis on the ACP has not been reported so far to our knowledge.

### Surgical Technique

The extradural removal of the anterior clinoid process was initially described by Dolenc for vascular lesions of the cavernous sinus.<sup>73</sup> Its use for pituitary adenomas, craniopharyngiomas, and clinoidal and tuberculum sellae meningiomas has been described.<sup>1,2</sup> Approach can be pterional,<sup>74</sup> orbitozygomatic,<sup>37,75</sup> modified pterional,<sup>76</sup> modified orbitozygomatic,<sup>40</sup> pretemporal transzygomatic transcavernous,<sup>39,77</sup> temporopolar epidural transcavernous transpetrous,<sup>78</sup> extended lateral supraorbital,<sup>79</sup> and endoscopic transsphenoidal.<sup>24</sup>

Extradural clinoidectomy has several advantages over intradural clinoidectomy. First, anatomical orientation is easily attained by identifying the dural extension into the SOF and the OC, and therefore a total ACP removal is possible. In contrast, when the intradural technique is used, both the extent of bone removal and the exposure that is gained may be limited. Second, the dura protects the intradural structures. Third, the procedure is performed during extradural exposure and also much faster than the intradural technique.<sup>76</sup>

With our first case report on the isolated metastasis of the anterior clinoid process, we provide an additional argument in favor of extradural clinoidectomy and in particular for malignant tumor pathology, since extradural resection minimizes the possibility of intradural tumor spread. Metastasis should now be included in the differential diagnosis of the lesions of the ACP. The possible spread of the metastatic disease intracranially in case of opening of the dura should be taken into consideration when planning a surgery.

### Conclusions

This is the first case report of an ACP metastasis. It was treated successfully with extradural clinoidectomy. Metastasis should now be included in the differential diagnosis on the lesions of the anterior clinoid process. Extradural clinoidectomy is a safe and effective method in the treatment of these tumors, minimizing the risk of intradural tumor spread.

#### Conflict of Interest

No financial or material support was accepted as part of this study. None of the authors have any financial relationships to disclose.

#### Acknowledgments

The authors wish to thank Andrew J. Gienapp, BA (Department of Medical Education, Methodist University Hospital, Memphis, Tennessee, United States, and Department of Neurosurgery, University of Tennessee Health Science


Center, Memphis, Tennessee, United States), for copy editing, preparation of the manuscript, table, and figures for publishing, and publication assistance with this manuscript.

### References

- Al-Mefty O. Clinoidal meningiomas. *J Neurosurg* 1990;73(06):840–849
- al-Mefty O, Ayoubi S. Clinoidal meningiomas. *Acta Neurochir Suppl (Wien)* 1991;53:92–97
- Aoyama Y, Ohtomo K, Sawamura H. Recurrent optic neuropathy caused by a mucocele of the anterior clinoid process after a 5-year remission: a case report and literature review. *Neuroophthalmology* 2014;38(05):281–285
- Arnavielle S, Vignal-Clermont C, Galatoire O, et al. Compressive optic neuropathy related to an anterior clinoid mucocele [in French]. *J Fr Ophtalmol* 2010;33(03):208.e1–208.e6
- Chagla AS, Bhaganagare A, Kansal R, Tyagi D. Complete recovery of visual loss following surgical treatment of mucopyocele of the anterior clinoid process. *J Clin Neurosci* 2010;17(05):670–672
- Chang DJ. The “no-drill” technique of anterior clinoidectomy: a cranial base approach to the paraclinoid and parasellar region. *Neurosurgery* 2009;64(3, Suppl):ons96–ons105, discussion ons105–ons106
- Cheong JH, Kim JM, Kim CH. Bony protuberances on the anterior and posterior clinoid processes lead to traumatic internal carotid artery aneurysm following craniofacial injury. *J Korean Neurosurg Soc* 2011;49(01):49–52
- Chou PI, Chang YS, Feldon SE, Chen JT. Optic canal mucocele from anterior clinoid pneumatization. *Br J Ophthalmol* 1999;83(11):1306–1307
- Chung DS, Park YS, Lee JH, Kang JK. Mucocele of the anterior clinoid process: case report. *Neurosurgery* 1999;45(02):376–378
- Deshmukh S, DeMonte F. Anterior clinoidal mucocele causing optic neuropathy: resolution with nonsurgical therapy. Case report. *J Neurosurg* 2007;106(06):1091–1093
- Dunya IM, Frangieh GT, Heilman CB, Miranda MR, Rand LI, Hedges TR. Anterior clinoid mucocele masquerading as retrobulbar neuritis. *Ophthalm Plast Reconstr Surg* 1996;12(03):171–173
- Forer B, Hui NY, Sethi DS. Unilateral ophthalmoplegia secondary to anterior clinoid process mucocele. *J Neuroophthalmol* 2010;30(04):321–324
- Garaventa G, Arcuri T, Schiavoni S, Fonzari M. Anterior clinoid mucocele: a trans-nasal endoscopic approach. *Minim Invasive Neurosurg* 1997;40(04):144–147
- Hejazi N, Witzmann A, Hassler W. Ocular manifestations of sphenoid mucoceles: clinical features and neurosurgical management of three cases and review of the literature. *Surg Neurol* 2001;56(05):338–343
- Higgins HL, Schimdt JH III. Atypical presentation of a dermoid brain cyst. *W V Med J* 1996;92(06):312–315
- Hong CS, Lehman NL, Sauvageau E. A pilocytic astrocytoma mimicking a clinoidal meningioma. *Case Rep Radiol* 2014;2014:524574
- Hopf-Jensen S, Rubarth O, von D Ahe I, et al. Isolated oculomotor nerve palsy caused by a mucocele of an aerated anterior clinoid process. *Clin Neuroradiol* 2014;24(02):161–164
- Johnson LN, Hepler RS, Yee RD, Batzdorf U. Sphenoid sinus mucocele (anterior clinoid variant) mimicking diabetic ophthalmoplegia and retrobulbar neuritis. *Am J Ophthalmol* 1986;102(01):111–115
- Kasliwal MK, Suri A, Gupta DK, Suri V, Rishi A, Sharma BS. Sphenoid wing inflammatory pseudotumor mimicking a clinoidal meningioma: case report and review of the literature. *Surg Neurol* 2008;70(05):509–513, discussion 513
- Kwon SH, Kim SH, Yoon JH. Anterior clinoid mucocele coexisting with sphenoid sinus mucocele. *Auris Nasus Larynx* 2009;36(05):598–600

- 21 Lim CC, Dillon WP, McDermott MW. Mucocele involving the anterior clinoid process: MR and CT findings. *AJNR Am J Neuroradiol* 1999;20(02):287–290
- 22 Mansour TR, Medhkour Y, Entezami P, Mrak R, Schroeder J, Medhkour A. The art of mimicry: anterior clinoid dural-based cavernous hemangioma mistaken for a meningioma. *World Neurosurg* 2017;100:708.e19–708.e22
- 23 Moisseiev E, Regenbogen M, Segev Y. Anterior clinoid process mucocele causing optic nerve compression [in Hebrew]. *Harefuah* 2013;152(02):76–78, 124
- 24 Nundkumar N, Mittal M, Kupsky WJ, Folbe A, Mittal S. Complete recovery of acute monocular visual loss following endoscopic resection of anterior clinoid mucocele: case report and review of the literature. *J Neurol Sci* 2012;312(1–2):184–190
- 25 O'Donnell TJ, Michael LM II, Laster R, Fleming JC. Isolated pyocele of anterior clinoid process presenting as a cavernous sinus syndrome. *Tenn Med* 2013;106(05):37–38, 43
- 26 Righini CA, Darouassi Y, Boubagra K, Schmerber S, Rey E. Sphenoid sinus mucocele of unusual aetiology and location [in French]. *Rev Laryngol Otol Rhinol (Bord)* 2006;127(03):165–170
- 27 Schwaighofer BW, Sobel DF, Klein MV, Zyroff J, Hesselink JR. Mucocele of the anterior clinoid process: CT and MR findings. *J Comput Assist Tomogr* 1989;13(03):501–503
- 28 Thurtell MJ, Besser M, Halmagyi GM. Anterior clinoid mucocele causing acute monocular blindness. *Clin Experiment Ophthalmol* 2007;35(07):675–676
- 29 Tobias S, Kim CH, Kosmorsky G, Lee JH. Management of surgical clinoidal meningiomas. *Neurosurg Focus* 2003;14(06):e5
- 30 Ushikoshi S, Honma T, Uchida K, Yasuda H, Ajiki M. Dural arteriovenous fistula at the anterior clinoid process draining directly into the superficial middle cerebral vein. *Neurol Med Chir (Tokyo)* 2013;53(03):195–198
- 31 Vaphiades MS, Yunker JJ, Roberson GH, Meyer DR, Mills DM. Optic neuritis is nothing to sneeze at. *Surv Ophthalmol* 2007;52(01):106–110
- 32 Wang AC, Than KD, Ramnath S, Pandey AS. Anterior clinoid mucocele presenting with orbital apex syndrome. *Surg Neurol Int* 2013;4:63
- 33 Yamashita T, Mikami T, Minamida Y, Baba T, Houkin K. Primary intraosseous cavernous hemangioma in anterior clinoid process [in Japanese]. *No Shinkei Geka* 2006;34(08):833–837
- 34 Drake CG, Vanderlinden RG, Amacher AL. Carotid-ophthalmic aneurysms. *J Neurosurg* 1968;29(01):24–31
- 35 Hauser MJ, Gass H. Optic nerve pressure by aneurysm relieved by decompression of optic nerve; report of a case. *AMA Arch Ophthalmol* 1952;48(05):627–631
- 36 Copeland WR, Van Gompel JJ, Giannini C, Eckel LJ, Koeller KK, Link MJ. Can preoperative imaging predict tumor involvement of the anterior clinoid in clinoid region meningiomas? *Neurosurgery* 2015;77(04):525–529, discussion 530
- 37 Arnautović KI, Al-Mefty O, Angtuaco E. A combined microsurgical skull-base and endovascular approach to giant and large paraclinoid aneurysms. *Surg Neurol* 1998;50(06):504–518, discussion 518–520
- 38 Krisht AF. Transcavernous approach to diseases of the anterior upper third of the posterior fossa. *Neurosurg Focus* 2005;19(02):E2
- 39 Hsu SP, Krisht AF, Lin CF, et al. Immediate results of microsurgical clipping of posterior communicating artery aneurysms using the pretemporal transclinoid approach. *J Chin Med Assoc* 2012;75(09):454–458
- 40 Noguchi A, Balasingam V, Shiokawa Y, McMenomey SO, Delashaw JB Jr. Extradural anterior clinoidectomy. Technical note. *J Neurosurg* 2005;102(05):945–950
- 41 Tan Y, Xiao S, Zhang C, et al. Microsurgical resection of anterior clinoid meningiomas – 46 cases report [in Chinese]. *Zhonghua Wai Ke Za Zhi* 2014;52(04):271–275
- 42 Attia M, Umansky F, Paldor I, Dotan S, Shoshan Y, Spektor S. Giant anterior clinoid meningiomas: surgical technique and outcomes. *J Neurosurg* 2012;117(04):654–665
- 43 Bassiouni H, Asgari S, Sandalcioğlu IE, Seifert V, Stolke D, Marquardt G. Anterior clinoid meningiomas: functional outcome after microsurgical resection in a consecutive series of 106 patients. Clinical article. *J Neurosurg* 2009;111(05):1078–1090
- 44 Pamir MN, Belirgen M, Ozduman K, Kiliç T, Ozek M. Anterior clinoid meningiomas: analysis of 43 consecutive surgically treated cases. *Acta Neurochir (Wien)* 2008;150(07):625–635, discussion 635–636
- 45 Nanda A, Konar SK, Maiti TK, Bir SC, Guthikonda B. Stratification of predictive factors to assess resectability and surgical outcome in clinoidal meningioma. *Clin Neurol Neurosurg* 2016;142:31–37
- 46 Tao CS, Lou MQ, Lu YC, et al. Experience of resection large clinoidal meningiomas [in Chinese]. *Zhonghua Wai Ke Za Zhi* 2005;43(21):1414–1417
- 47 Puzzilli F, Ruggeri A, Mastronardi L, Agrillo A, Ferrante L. Anterior clinoid meningiomas: report of a series of 33 patients operated on through the pterional approach. *Neuro-oncol* 1999;1(03):188–195
- 48 Goel A, Gupta S, Desai K. New grading system to predict resectability of anterior clinoid meningiomas. *Neurol Med Chir (Tokyo)* 2000;40(12):610–616, discussion 616–617
- 49 Risi P, Uske A, de Tribolet N. Meningiomas involving the anterior clinoid process. *Br J Neurosurg* 1994;8(03):295–305
- 50 Romani R, Laakso A, Kangasniemi M, Lehecka M, Hernesniemi J. Lateral supraorbital approach applied to anterior clinoid meningiomas: experience with 73 consecutive patients. *Neurosurgery* 2011;68(06):1632–1647, discussion 1647
- 51 Sade B, Lee JH. High incidence of optic canal involvement in clinoidal meningiomas: rationale for aggressive skull base approach. *Acta Neurochir (Wien)* 2008;150(11):1127–1132, discussion 1132
- 52 Lee JH, Jeun SS, Evans J, Kosmorsky G. Surgical management of clinoidal meningiomas. *Neurosurgery* 2001;48(05):1012–1019, discussion 1019–1021
- 53 Cui H, Wang Y, Yin YH, Fei ZM, Luo QZ, Jiang JY. Surgical management of anterior clinoid meningiomas: a 26-case report. *Surg Neurol* 2007;68(Suppl 2):S6–S10, discussion S10
- 54 Mariniello G, de Divitiis O, Seneca V, Maiuri F. Classical pterional compared to the extended skull base approach for the removal of clinoidal meningiomas. *J Clin Neurosci* 2012;19(12):1646–1650
- 55 Yang YM, Jiang HZ, Sha C, Yuan QG, Xie HW, Wang DM. Microsurgical management of anterior clinoid meningiomas [in Chinese]. *Zhonghua Yi Xue Za Zhi* 2010;90(25):1764–1766
- 56 Kim JH, Jang WY, Jung TY, et al. Predictive factors for surgical outcome in anterior clinoid meningiomas: analysis of 59 consecutive surgically treated cases. *Medicine (Baltimore)* 2017;96(15):e6594
- 57 Chernov SV, Rzaev DA, Kalinovskiy AV, et al. Early postoperative results of surgical treatment of patients with anterior clinoid meningiomas [in Russian]. *Vopr Neirokhir* 2017;81(01):74–80
- 58 Czernicki T, Kunert P, Nowak A, Marchel A. Results of surgical treatment of anterior clinoid meningiomas - our experiences. *Neurol Neurochir Pol* 2015;49(01):29–35
- 59 Watts J, Box G, Galvin A, Brochie P, Trost N, Sutherland T. Magnetic resonance imaging of meningiomas: a pictorial review. *Insights Imaging* 2014;5(01):113–122
- 60 Altay T, Krisht KM, Couldwell WT. Sellar and parasellar metastatic tumors. *Int J Surg Oncol* 2012;2012:647256
- 61 Gupta RK, Saran RK, Jagetia A, Narang P. Extra-axial dural cavernous hemangioma with dural tail sign, masquerading as meningioma. *J Neurosci Rural Pract* 2016;7(04):615–616
- 62 Azarpira N, Noshadi P, Pakbaz S, Torabineghad S, Rakei M, Safai A. Dural plasmacytoma mimicking meningioma. *Turk Neurosurg* 2014;24(03):403–405
- 63 Morgenstern P, Pisapia D, Ramakrishna R. Calvarial plasmacytoma mimicking meningioma as the initial presentation of multiple myeloma. *Cureus* 2017;9(03):e1126

- 64 Yang G, Li C, Chen X, et al. Large capillary hemangioma of the temporal bone with a dural tail sign: a case report. *Oncol Lett* 2014;8(01):183–186
- 65 Harrison CJ, Martin SC, Hofer M, Corkill R, Jeyaretna DS, Griffiths SJ. More than meets the MRI: case report of a carcinoid tumour metastasis mimicking a meningioma. *Br J Neurosurg* 2017;1–2. doi: 10.1080/02688697.2017.1327018
- 66 Zagzoog N, Ra G, Koziarz A, et al. Metastatic liposarcoma of the skull base: a case report and review of literature. *Neurosurgery* 2017;80(04):219–223
- 67 Malhotra G, Asopa RV, Sridhar E. Unusual case of isolated parasellar metastasis from carcinoma of thyroid. *Clin Nucl Med* 2013; 38(02):145–148
- 68 Lin NU, Bellon JR, Winer EP. CNS metastases in breast cancer. *J Clin Oncol* 2004;22(17):3608–3617
- 69 Gabos Z, Sinha R, Hanson J, et al. Prognostic significance of human epidermal growth factor receptor positivity for the development of brain metastasis after newly diagnosed breast cancer. *J Clin Oncol* 2006;24(36):5658–5663
- 70 Aversa C, Rossi V, Geuna E, et al. Metastatic breast cancer subtypes and central nervous system metastases. *Breast* 2014;23(05): 623–628
- 71 Leone JP, Lee AV, Brufsky AM. Prognostic factors and survival of patients with brain metastasis from breast cancer who underwent craniotomy. *Cancer Med* 2015;4(07):989–994
- 72 Leone JP, Leone BA. Breast cancer brain metastases: the last frontier. *Exp Hematol Oncol* 2015;4:33
- 73 Dolenc V. Direct microsurgical repair of intracavernous vascular lesions. *J Neurosurg* 1983;58(06):824–831
- 74 Dolenc VV. A combined epi- and subdural direct approach to carotid-ophthalmic artery aneurysms. *J Neurosurg* 1985;62(05): 667–672
- 75 Day JD, Giannotta SL, Fukushima T. Extradural temporopolar approach to lesions of the upper basilar artery and infrachiasmatic region. *J Neurosurg* 1994;81(02):230–235
- 76 Yonekawa Y, Ogata N, Imhof HG, et al. Selective extradural anterior clinoidectomy for supra- and parasellar processes. Technical note. *J Neurosurg* 1997;87(04):636–642
- 77 Krisht AF, Kadri PA. Surgical clipping of complex basilar apex aneurysms: a strategy for successful outcome using the pretemporal transzygomatic transcavernous approach. *Neurosurgery* 2005;56(2, Suppl):261–273, discussion 261–273
- 78 Roche PH, Mercier P, Fournier HD. Temporopolar epidural transcavernous transpetrous approach. Technique and indications [in French]. *Neurochirurgie* 2007;53(01):23–31
- 79 Andrade-Barazarte H, Jägersberg M, Belkhair S, et al. The extended lateral supraorbital approach and extradural anterior clinoidectomy through a frontopterio-orbital window: technical note and pilot surgical series. *World Neurosurg* 2017; 100:159–166



THIEME